



National Board of Examinations - Journal of Medical Sciences
Volume 3, Issue 5, Pages 608–612, May 2025
DOI 10.61770/NBEJMS.2025.v03.i05.012

CASE REPORT

Pilonidal Sinus Over Nasal Dorsum: Incidental Finding

Manav Jindal,^{1,*} Ashutosh Soni,² Sanjeev Agarwal,³ Arjun Chaudhary¹ and Dhruv Dodiya¹

¹Resident, Department of General surgery, Geetanjali Medical College and Hospital, Udaipur

²Senior Professor and Head, Department of Plastic and Reconstructive Surgery, Geetanjali Medical College and Hospital, Udaipur

³Professor and Head, Department of General Surgery, Geetanjali Medical College and Hospital, Udaipur

Accepted: 22-March-2025 / Published Online: 5-May-2025

Abstract

Pilonidal refers to a collection of hair. The pilonidal sinus is a subcutaneous track containing hairs or their microscopic fragments. The sinus penetrates into the subcutaneous layers as a bulbous diverticulum with or without branching side channels. The presence of a hair tuft in the sinus cavity or tract is the characteristic feature of the pilonidal sinus. We describe the case of a 13-year-old paediatric patient in this case study who developed a chronic, intermittently discharging sinus tract on the dorsum of the nose, Magnetic resonance imaging (MRI) of PNS showed a localized blind subcutaneous tract over the dorsal aspect of nose. A tiny area of abnormal signal intensity along the dorsal aspect of lower 1/3rd of nose reaching upto skin surface, however no obvious intranasal cavity opening or aspirable pocket or collection noted, possibly sinus tract. The patient has a presence of a sinus tract over the dorsum of nose; surgery was performed with exploration of the sinus by injecting methylene blue dye which subsequently facilitated a precise excision, ensuring complete removal of the sinus, through external *rhinoplasty* approach. Histopathological analysis revealed a sinus tract lined with keratinized stratified squamous epithelium containing a tuft of hair, patient was followed up for three months; without any complaint of any complication or recrudescence.

Keywords: Pilonidal sinus, unusual sites, atypical locations, Sinus tract, Nasal dorsum

*Corresponding Author: Manav Jindal
Email: manavjindal951@gmail.com

Introduction

One typical issue with the anorectum is pilonidal disease that primarily affects younger individuals, typically found in age group of 15 to 40 years. It is caused by shed hair which are drawn into the subcutaneous tissue. Hair can become damaged due to friction, leading to breakage, this can result in the hair entering through the open mouth of the sweat gland or penetrating the softened skin, which may occur due to sweat or dermatitis. The typical symptoms include pain and discharge. The nature of pain can range from dull ache to throbbing pain. Discharge can vary from a minimal amount of fluid to a sudden outpouring of pus.

Pilonidal sinus, mostly occur in the sacrococcygeal region, but it can also occur across various anatomical sites. Cases involving nasal structures, such as the nasal bridge and preauricular region, highlight the diverse clinical spectrum of this condition [1-4]. Furthermore, reports of pilonidal sinus in unusual sites like the umbilicus, interdigital spaces, give evidence that this ailment can occur anywhere in the body with hair follicles [4,8]. It can occur in hairdressers, dog groomers, jeep drivers and sheep shearers which shows that it is an occupational disease [5]. This review aims to synthesize the diverse array of reported cases, shedding light on the evolving understanding of pilonidal sinus manifestations across the human body.

Case Report

A 13-year-old paediatric male patient, has presented to our outpatient

clinic with complaint of discharging sinus on nasal bridge. The intermittent discharge over the past four years suggests a chronic inflammatory process, possibly indicative of a sinus tract.

A very small visible opening was present over the lower part of nasal dorsum. There was absence of palpable swelling or discharge upon examination which poses a diagnostic challenge, emphasizing the importance of imaging studies. The magnetic resonance imaging (MRI) findings suggestive of a tiny area of abnormal signal intensity of size 2.8mm × 3mm noted along dorsal aspect of lower 1/3rd part of nose reaching upto skin surface, however no obvious intranasal cavity opening or aspirable pocket of collection noted, possibly sinus tract.

Surgical excision of sinus was done under general anaesthesia by giving a midline incision over the nasal dorsum starting from the sinus opening (Figure 3). The intraoperative tracing of the sinus tract with dye injection facilitated precise excision, ensuring complete removal of the sinus through dissection from the neighbouring tissues (Figures 1 and 2). Closure of the cavity was done in two layers. On cutting & opening the sinus we found that there was a tuft of hair, present inside the sinus wall.

The sinus was then sent for histopathological examination. The specimen was identified as a pilonidal sinus which confirmed the diagnosis. No new complaints developed during the post-operative and follow-up period (Figure 4).

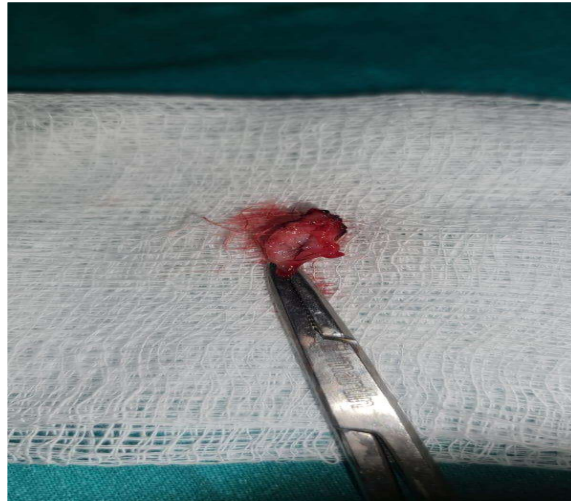


Figure 1. The Specimen shows an epithelial lined sinus tract with a tuft of hair.

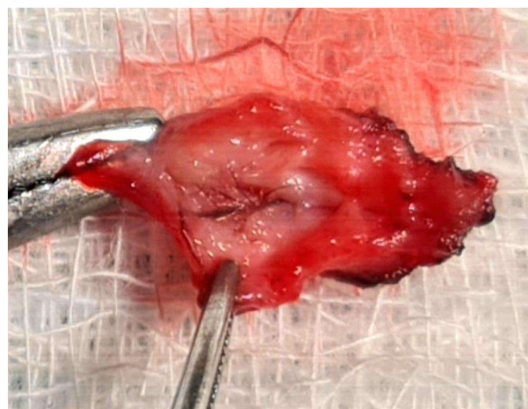


Figure 2. Specimen of Excision of Sinus.

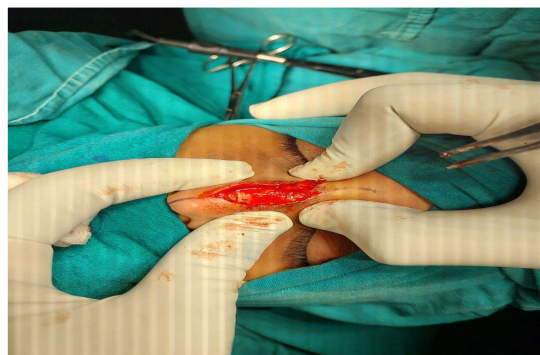


Figure 3. Intra operative image of nasal dorsum.

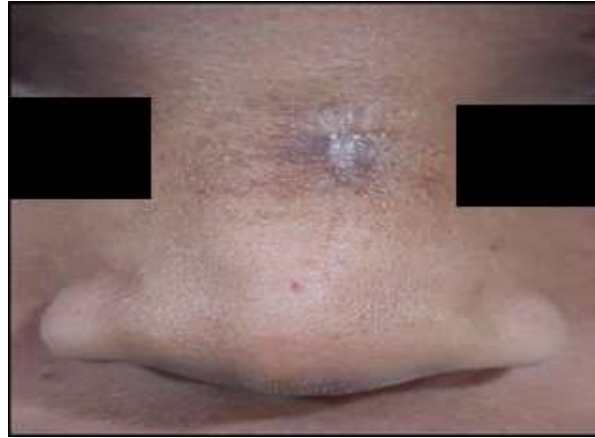

Figure 4. Clinical photograph of patient on follow up after 1 month.

Discussion

A condition known as the pilonidal sinus is present in the natal cleft situated above the coccyx, include of one or more, typically uninfected, midline openings, which connects with a fibrous track that is lined by granulation tissue and consisting of loose hair in the lumen. The pilonidal sinus is mainly composed of 3 contents; granulation tissue, epithelial scars and debris and dead hairs which may resting loosely in the sinus, situated within granulation tissue and deep within the developed scar tissue [6,7]. It is mainly occur in dark haired hirsute man, obese male and in individuals whose occupations typically linked to friction and shearing forces [9,10]. These risk factors are not present in our patient.

While many patients show no symptoms, a few of the patient establish pain, local infection, discharge and hyperaemia. The complications of pilonidal sinus include recurrent inflammation, abscess formation and recurrence of sinus [11]. Recurrence is probably due to the inadequate excision, entry of new hair through the scar or skin.

Management modalities vary depending on factors such as the site of involvement, disease severity, recurrence, patient comorbidities, cosmetic concerns and patient preferences [12]. While surgical excision remains the definitive management in many cases [13]. Abscess formation requires drainage of the pus or fluid present in the sinus tract lumen.

Furthermore, the role of patient education and lifestyle modifications helps in prevention of pilonidal sinus disease. Encouraging measures such as regular hygiene practices, weight management, and avoidance of prolonged sitting, friction movements may reduce the likelihood of recurrence. Further research should be done to explore the aetiology and management strategies for pilonidal sinus in atypical locations like the nasal dorsum.

Conclusion

Pilonidal sinus disease includes a range of symptoms, diagnostic difficulties, and treatment options. More research is needed to better understand the condition, improve diagnosis, and develop better treatment plans. Pilonidal sinus in the nasal area, like in our case, is very uncommon.

Statements and Declarations

Conflict of interest

In relation to the research, writing, and publication of this work, the authors hereby affirm that they possess no conflict of interest.

Ethics approval

Informed consent for publication was obtained from the parents and The Institutional Ethics Committee gave their approval to the case review.

Competing interests

Authors declare that they have no competing interests.

Funding

No funding was received for conducting this study.

References

1. Paulose KO, al Khalifa S, Raj SS, Saeed T. Pilonidal sinus of the nose. *J Laryngol Otol*. 1989;103(12):1210-3.
2. Sreedharan S, Kamath PM, Hegde MC, Lobo FD. Pilonidal sinus of nose—a diagnostic dilemma. *Jurnalul de Chirurgie*. 2010;6:343-7
3. Junaid, M., Ahmed, S. Q., Kazi, M., & Ali, N. S. (2015). Pilonidal sinus involving the nasal bridge: A rare manifestation. *BMJ Case Reports*. <https://doi.org/10.1136/bcr-2015-209948>
4. Patey Dh, Scarff Rw. Pilonidal sinus in a barber's hand with observations on postanal pilonidal sinus. *Lancet*. 1948;2(6514):13. doi: 10.1016/s0140-6736(48)91791-7.
5. Brearley R. Pilonidal sinus – a new theory of origin. *Br J Surg*. 1955;43:62-7.
6. Karydakakis GE. Easy and successful treatment of pilo-nidal sinus after explanation of its causative process. *Aust N Z J Surg*. 1992;62:385–9.
7. Buie LA, Curtiss RK. Pilonidal disease. *Surg Clin North Am* 1952; 32: 1247-59.
8. Clery AP. Clery AB. Pilonidal disease of the umbilicus. *Brit J Surg* 1963;50:666-9.
9. Weal FE. A comparison of barber's and postanal pilonidal sinus. *Brit J Surg* 1964;51:513-6.
10. Goodall P. The etiology and treatment of pilonidal sinus. *Brit J Surg* 1961;49:212-8.
11. Colapinto ND. Umbilical pilonidal sinus. *Brit J Surg* 1977; 64: 494-5.
12. Mayer DG. Pilonidal cyst of the scalp. *Arch Dermatol* 1972;105:578-9.
13. Kars A, Atalay F, Kilic K, Bingöl F, Can Y. Rare Location for Pilonidal Sinus: the Nasal Dorsum. *J Craniofac Surg*. 2018;29(6):e556-e557. doi: 10.1097/SCS.0000000000004539.