



ORIGINAL ARTICLE

A Prospective Study on Manipulation with Hydrodilatation and Steroid Injection in the Management of Frozen Shoulder

V. Ramson,^{1,*} T. Thirumalaiswamy² and Ranjithkumar R¹

¹Assistant Professor, Department of Orthopaedics, Government Medical College and ESIC Hospital, Coimbatore, Tamil Nadu

²Associate Professor, Department General Surgery, Dhanalakshmi Srinivasan Medical College, Siruvachur, TamilNadu

Accepted: 12-April-2026 / Published Online: 6-May-2026

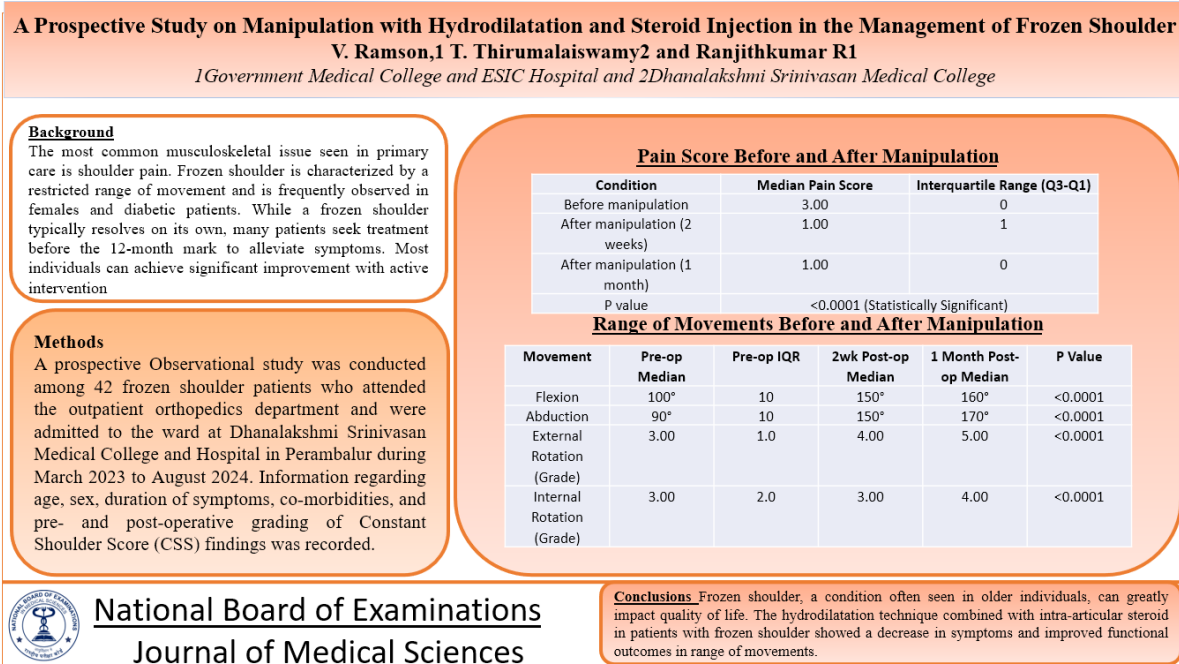
Abstract

Background: The most common musculoskeletal issue seen in primary care is shoulder pain. Frozen shoulder is characterized by a restricted range of movement and is frequently observed in females and diabetic patients. While a frozen shoulder typically resolves on its own, many patients seek treatment before the 12-month mark to alleviate symptoms. Most individuals can achieve significant improvement with active intervention. **Objective:** To evaluate the pain severity and range of movements in patients with frozen shoulders using the Constant Shoulder Score (CSS) after manipulation with hydrodilatation and steroid treatment. **Methodology:** A prospective Observational study was conducted among 42 frozen shoulder patients who attended the outpatient orthopedics department and were admitted to the ward at Dhanalakshmi Srinivasan Medical College and Hospital in Perambalur during March 2023 to August 2024. Information regarding age, sex, duration of symptoms, co-morbidities, and pre- and post-operative grading of Constant Shoulder Score (CSS) findings was recorded. **Results:** Frozen shoulder was commonly observed in females between 40 and 49 years of age, with the left shoulder most frequently affected. Diabetes mellitus was the most commonly associated risk factor. Following manipulation using the hydrodilatation technique and steroid injection, there was a significant improvement in shoulder pain and range of movements, assessed using Constant Shoulder Score ($p=0.000$). **Conclusion:** Frozen shoulder, a condition often seen in older individuals, can greatly impact quality of life. The hydrodilatation technique combined with intra-articular steroid in patients with frozen shoulder showed a decrease in symptoms and improved functional outcomes in range of movements. This treatment is also cost-effective and allows for early mobilization and return to day-to-day activities.

Keywords: Frozen shoulder, Periarthritis shoulder, Hydrodilatation technique, Intra-articular corticosteroid injection, Constant shoulder score

*Corresponding Author: V. Ramson
Email: vtramu@gmail.com

Graphical Abstract



Introduction

Shoulder pain is the third most frequent musculoskeletal problem. In primary care, the reported yearly incidence of shoulder discomfort is 14.7 per 1000 patients per year, with a lifetime prevalence of up to 70% [1]. Frozen shoulder (adhesive capsulitis) is a common debilitating disorder characterized by shoulder pain and progressive loss of shoulder movement [2]. The American Shoulder and Elbow Surgeons' currently accepted definition is "a condition of uncertain etiology characterized by significant restriction of both active and passive shoulder motion that occurs in the absence of a known intrinsic shoulder disorder" [3].

Neviaser coined the term "adhesive capsulitis" for the idiopathic form of shoulder mobility loss caused by capsular contractures and adhesions. Patients with idiopathic stiffness are typically between the ages of 40 and 60, with the non-dominant arm more commonly implicated [2]. Women account for roughly 70% of

patients. In 20% to 30% of those affected, the problem rarely returns in the same shoulder [4].

Adhesive capsulitis affects approximately 2-5% of the general population, with a higher prevalence in patients with diabetes mellitus (up to 20%), thyroid disorders, prolonged immobilization, hyperlipidemia, cerebrovascular accident or myocardial ischemia, and autoimmune diseases [1,5]. Millar et al. (2022) described frozen shoulder as a fibroproliferative disorder characterized by fibroblast transformation into myofibroblasts, accompanied by inflammation, neoangiogenesis and neoinnervation leading to capsular fibrotic contracture [2].

The association between diabetes mellitus and frozen shoulder is well established. Dyer et al. (2023) conducted a systematic review and meta-analysis of six longitudinal observational studies and found that people with diabetes had 3.69 (95% CI 2.99 to 4.56) times the risk of

developing frozen shoulder compared to those without diabetes [5]. Kim et al. (2023) confirmed in a large nationwide population-based study that both prediabetes and type 2 diabetes significantly increase the risk of shoulder adhesive capsulitis [6].

The reduction in passive range of movements is important to determine the presence of frozen shoulder. Frozen shoulder is a self-limiting illness that lasts 12 to 18 months in most patients with no long-term consequences; however, approximately 10% of people suffer long-term issues [2]. Treatment options include supervised physical therapy, nonsteroidal anti-inflammatory medications, oral corticosteroids, intraarticular steroid injections, hydrodistension, closed manipulation, and arthroscopic capsular release [7].

First described by Andren and Lundberg in 1965, hydrodilatation involves injecting a large volume of fluid (80–100 ml normal saline) into the shoulder joint to dilate the capsule. This causes capsular rupture and is both minimally invasive and technically simple. Lädemann et al. (2021), in an overview of meta-analyses, found that arthrographic distension/hydrodilatation with corticosteroid is the most effective conservative management for frozen shoulder, providing superior pain relief in the short term and improvement in ROM across all time frames [8].

Poku et al. (2023) in a systematic review and meta-analysis published in British Medical Bulletin confirmed that hydrodilatation leads to at least transient improvements in shoulder disability and passive external rotation compared with intra-articular corticosteroid injections alone [9]. Although arthroscopic capsular

release is effective, it is more invasive and costly compared to hydrodilatation [10].

There is limited literature available in South India regarding the combined impact of corticosteroids and hydrodilatation for frozen shoulder. The current study evaluates both intra-articular steroids and hydrodilatation to enhance the functional outcome of periarthritic shoulder patients in a tertiary care setting.

Materials And Methods

A prospective Observational study was conducted among patients with periarthritis shoulder who were admitted in the Department of Orthopedics at Dhanalakshmi Srinivasan Medical College Hospital, a tertiary care teaching hospital located in Siruvachur, Perambalur, were enrolled during the period of March 2023 to August 2024. Participants aged 18 to 75 years, of either gender, presenting with restricted active and passive shoulder movements and experiencing worsening of symptoms despite undergoing physiotherapy and analgesic treatment for a duration exceeding one month were included in the study. Exclusion criteria comprised the presence of glenohumeral arthritis, any history of prior shoulder surgery, previous shoulder dislocation or fracture-dislocation, malignancy, post-infective conditions, rotator cuff tear, and psychological disorders such as dementia. By universal sampling method, all 42 patients who satisfied the inclusion and exclusion criteria during the study period were included in the study.

Pre-operative Assessment

A detailed history was taken with reference to the frozen shoulder. A preliminary general physical examination was done. Systemic examination of CVS,

Respiratory, and GI was performed routinely. All active shoulder movements were measured using a goniometer. Pre-operative pain score as assessed by VAS, range of movements, and functional ability were documented using Constant Shoulder Score (CSS).

Inspection

The patient's two shoulders were sufficiently exposed to compare and the following observations were made

1. Attitude
2. Scar, sinus and swelling
3. Deformities

4. Muscle wasting

Palpation

Local warmth, tenderness over joint and bony prominence, swelling are noted.

Movements

All active shoulder movements measured. Forward flexion measured with the patient in a standing lateral position and measured the angle between the arm and chest using a goniometer (Figure 1).

Abduction is measured in standing position using goniometer angle between arm and trunk noted (Figure 2).



Figure 1. Measurement of Forward flexion



Figure 2. Measurement of Forward flexion

External Rotation is noted based on level of hand behind or above head with level of elbow held forward or back. Active Internal Rotation noted based on the level of hand back to lateral thigh, back to the buttock, back to Lumbosacral junction, back to L3 spine, back to D12 spine, and interscapular level. Pre-op pain score, range of movements, and functional ability documented using Constant shoulder score (CSS).

Investigations

Before starting treatment, the following routine investigations were carried out: Complete Blood Count, Blood Sugar values, Urine Complete, Renal

Function Test (Urea and Creatinine), Viral markers (HIV, HBsAg, HCV), X-ray AP view of shoulder joint. Further treatment was initiated only after blood sugar control in diabetic patients.

Operative Procedure

Patient in beach chair position; shoulder painted and draped under strict aseptic precaution. Anatomical landmarks (angle of acromion and coracoid process) were marked. An 18-gauge spinal needle was inserted into the shoulder joint through a posterior approach under fluoroscopy guidance (1 cm inferior to the angle of the acromion, directed towards coracoid process) (Figure 3).

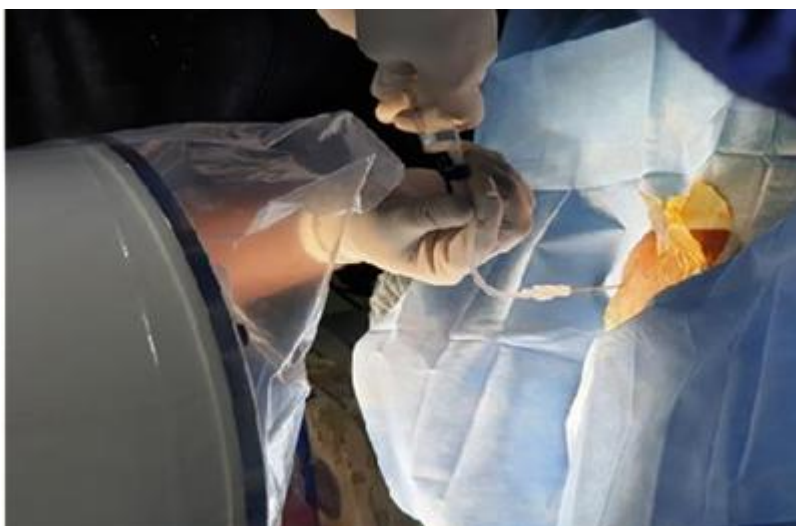


Figure 3. Injection of Omnipaque contrast dye (Iohexol)

2 ml omnipaque contrast dye (iohexol) was injected and needle position confirmed under fluoroscopy. 80 mg Triamcinolone and 5 ml local anesthetic agent (2% lignocaine 2 ml + 0.5% Bupivacaine 3 ml) injected for postoperative pain relief. 80 ml of cold normal saline was injected into the joint using a 3-way adaptor. Shoulder manipulation was performed using a short lever arm with a fixed scapula — flexion,

extension, abduction, adduction, external and internal rotation. Post-procedure fluoroscopy image was taken to rule out fractures.

Post-Operative Protocol

Adequate post-operative analgesics given. Intravenous antibiotics — 3 doses. Immediate shoulder ROM exercises initiated once patient recovered from anesthesia. Patient pain score (VAS) and

ROM documented at immediate post-op, 2 weeks, and 1 month using Constant Shoulder Score (CSS). Physiotherapy continued for 3 months post-operatively.

The procedures were performed by multiple orthopedic surgeons; however, all interventions were carried out following a standardized institutional protocol to ensure consistency in technique. Furthermore, all patients were managed with a uniform post-procedure physiotherapy protocol.

Statistical Analysis

Data were analysed using paired sample T-test or Wilcoxon signed-rank whichever applicable. For all statistical evaluations, p-value <0.05 was considered statistically significant. All analyses were performed using SPSS software.

Results

This prospective study enrolled 42 patients with frozen shoulder. The majority were between 40-49 years of age (40.50%), followed by 60-69 years (26.20%) and 50-59 years (21.40%). Of the 42 patients, 28 were female and 14 were male; the female sex (66.7%) was most frequently affected. The left shoulder was predominantly affected (66.7%) compared to the right shoulder (33.3%). Co-morbidities identified included: diabetes mellitus in 16 patients (44.4%), hypertension in 2, bronchial asthma in 2, peptic ulcer disease in 1, chronic kidney disease in 1, and thyroid/seizure disorder in 1 each.

Table 1. Pain Score Before and After Manipulation

| Condition | Median Pain Score | Interquartile Range (Q3-Q1) |
|------------------------------|-------------------------------------|------------------------------------|
| Before manipulation | 3.00 | 0 |
| After manipulation (2 weeks) | 1.00 | 1 |
| After manipulation (1 month) | 1.00 | 0 |
| P value | <0.0001 (Statistically Significant) | |

Following manipulation, all 42 patients experienced a considerable reduction in pain. Before starting MUA, the median pain score was 3.00; by the end of

1 month, it had dropped to 0. The P value was statistically significant (p<0.0001) (Table 1).

Table 2. Range of Movements Before and After Manipulation

| Movement | Pre-op Median | Pre-op IQR | 2wk Post-op Median | 1 Month Post-op Median | P Value |
|---------------------------|----------------------|-------------------|---------------------------|-------------------------------|----------------|
| Flexion | 100° | 10 | 150° | 160° | <0.0001 |
| Abduction | 90° | 10 | 150° | 170° | <0.0001 |
| External Rotation (Grade) | 3.00 | 1.0 | 4.00 | 5.00 | <0.0001 |
| Internal Rotation (Grade) | 3.00 | 2.0 | 3.00 | 4.00 | <0.0001 |

There was significant improvement in all ROM following manipulation. Flexion improved from median 100° to 160°, abduction from 90° to 170°, external

rotation from grade 3 to grade 5, and internal rotation from grade 3 to grade 4. All P values were <0.0001, which is statistically significant (Table 2).

Table 3. Grading of Constant Shoulder Score Before and After Manipulation

| Description of CSS | Grade | Pre-op (n) | Immed. POD1 (n) | POD 2 wks (n) | POD 1 Month (n) | Pre-op % | POD 2 wks % | POD 1 Month % |
|--------------------|-------|------------|-----------------|---------------|-----------------|----------|-------------|---------------|
| Poor (0–55) | 1 | 42 | 19 | 3 | 2 | 100 | 7.1 | 4.8 |
| Mediocre (56–70) | 2 | 0 | 19 | 16 | 5 | 0 | 38.1 | 11.9 |
| Good (71–85) | 3 | 0 | 4 | 19 | 8 | 0 | 45.2 | 19.0 |
| Excellent (86–100) | 4 | 0 | 0 | 4 | 27 | 0 | 9.5 | 64.3 |

The functional assessment in the range of movements of the shoulder was assured using a constant shoulder score. In this study, Out of 42 patients, 27 showed excellent cores (64.3%), 8 showed good

results (19.0%) and 2 showed poor performance (4.8%) (Table 3).

Figures 4-6 shows the Pre-operative, Intra-operative and 1 month Post-operative representative images.



Figure 4. Pre-Operative images (Representative)

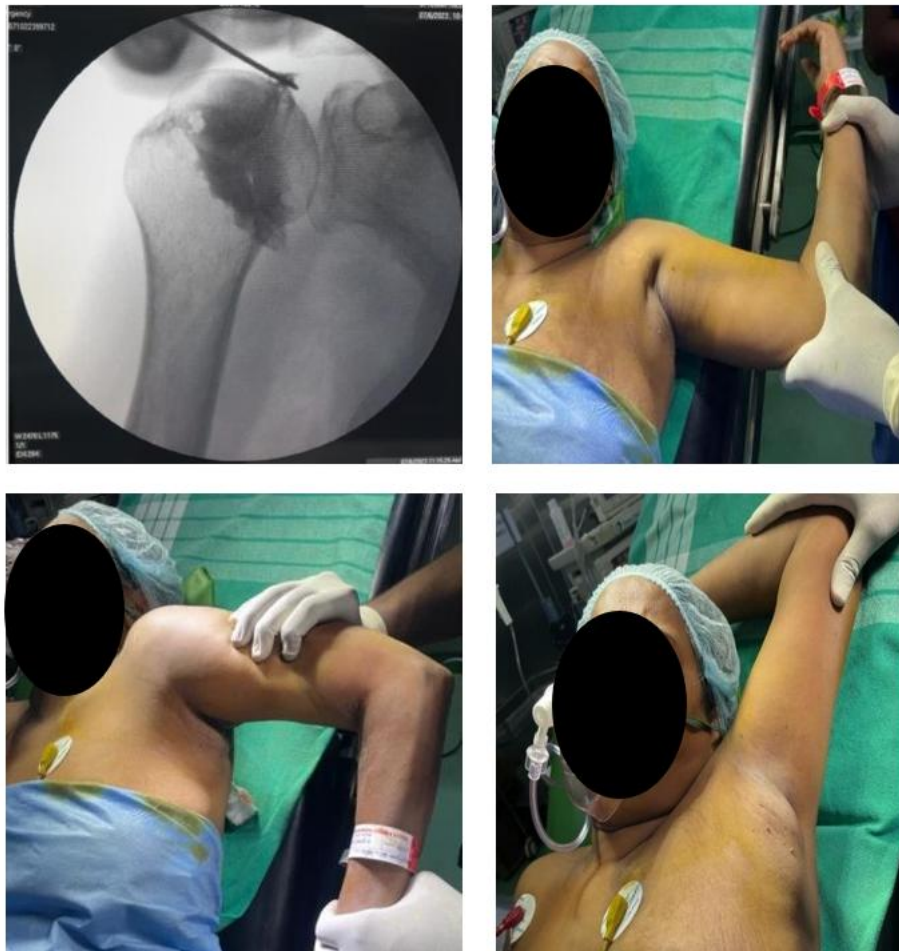

Figure 5. Intra-Operative images (Representative)

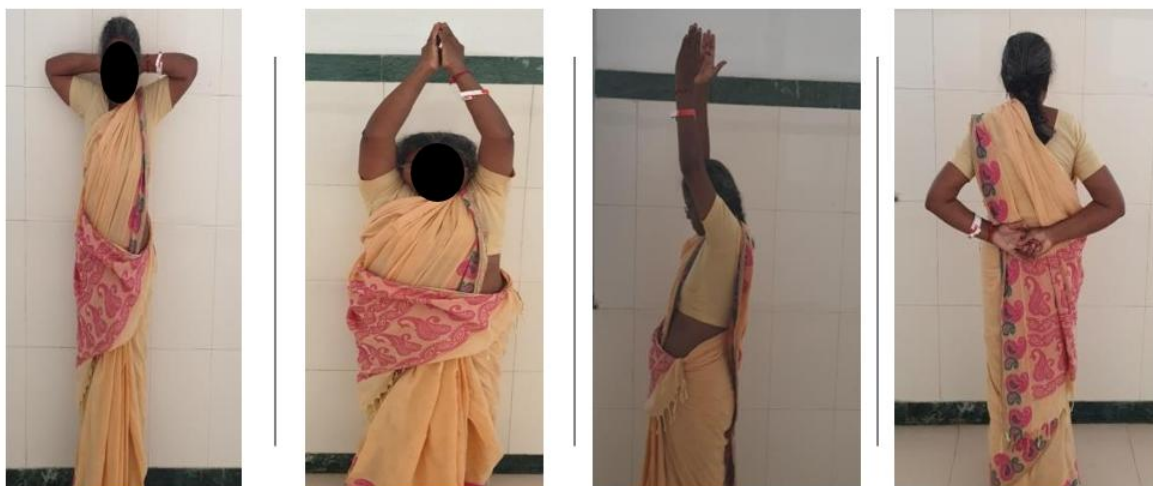

Figure 6: 1-month post-operative images (Representative)

Discussion

This prospective study evaluated the range of movements and pain using a Constant Shoulder Score after manipulation with hydrodilatation in 42 frozen shoulder patients over a 17-month period. Our findings are consistent with recent literature confirming the efficacy of hydrodilatation combined with intra-articular corticosteroid for frozen shoulder management.

In the present study, most cases belonged to the 40–49 age group (40.50%), consistent with the epidemiological data from Millar et al. (2022) who reported frozen shoulder most commonly in the fifth and sixth decades of life [2]. A similar age distribution was noted by Kraal et al. (2020) in their scoping review of frozen shoulder pathophysiology [11]. Pandey and Madi (2021) in their Indian clinical guidelines update also reported peak incidence in the 40–60 age group [7].

Female predominance was observed in our study (66.7%), which is in keeping with available literature. Millar et al. (2022) reported that frozen shoulder affects approximately 8% of men and 10% of women globally, with a slight female preponderance [2]. StatPearls (2023) confirms a female-to-male ratio of approximately 1.4:1 with hormonal and immunological factors contributing to this disparity [3].

Left shoulder involvement was more frequent in our study (66.7%) — consistent with published data indicating greater involvement of the non-dominant arm. Frozen shoulder is known to preferentially affect the non-dominant extremity, possibly due to differential use patterns and biomechanical stress responses [3,12].

Diabetes mellitus was the most commonly associated risk factor (44.4%) in

this study. This is strongly supported by recent evidence. Dyer et al. (2023) in a systematic review and meta-analysis found diabetes confers a 3.69 times higher risk for developing frozen shoulder (95% CI 2.99 to 4.56). [5] Kim et al. (2023) in a nationwide longitudinal cohort study confirmed that both prediabetes and type 2 diabetes significantly increase the risk of adhesive capsulitis. [6] Dyer et al. (2021) further demonstrated that diabetic patients with frozen shoulder may experience worse long-term outcomes than non-diabetic counterparts [13].

In the present study, following manipulation with hydrodilatation and steroid injection, all 42 patients experienced a significant reduction in pain (median pain score decreased from 3.00 to 0 at one month). This is comparable to results reported by Avulapatti et al. who found mean VAS scores decreased from 7.29 to 1.71 at four months following manipulation under anesthesia [14]. Latzka et al. (2023) in a comparative study found that hydrodilatation achieved equivalent or superior outcomes compared to corticosteroid injection alone for adhesive capsulitis [10].

Regarding range of movements, flexion improved from median 100° to 160° and abduction from 90° to 170°. Yao et al. (2024) in a systematic review and meta-analysis confirmed that hydrodistension combined with conventional treatment provided significantly better analgesic effect and improved mobility function compared with other treatment measures [15]. Wang et al. (2023) demonstrated in a randomized controlled trial that ultrasound-guided glenohumeral hydrodilatation significantly improved range of motion in adhesive capsulitis patients [16].

Lädemann et al. (2021), in an overview of eight meta-analyses, concluded that arthrographic distension/hydrodilatation with corticosteroid provides superior pain relief in the short term and improvement in ROM across all time frames for frozen shoulder when compared to corticosteroid injection alone or physiotherapy [8]. Poku et al. (2023) corroborated these findings, stating that hydrodilatation leads to at least transient marked improvements in shoulder disability and passive external rotation [9].

Manipulation under anesthesia (MUA) combined with hydrodilatation remains a safe and effective intervention for refractory frozen shoulder. Song et al. (2021) in a retrospective cohort study of 141 patients found that MUA combined with intra-articular steroid injection significantly improved pain severity and shoulder function compared to MUA alone [17]. Xu et al. (2022) in a randomized controlled trial using the Constant-Murley Score as the primary outcome confirmed MUA significantly improved functional outcomes in secondary frozen shoulder [18].

Salomon et al. (2022) in a systematic review of randomized controlled trials noted that MUA was not inferior to cortisone injections with hydrodilatation in terms of pain reduction and functional improvement [19]. Kraal et al. (2024) in a randomized controlled trial found that MUA provided better ROM in the short term compared to physiotherapy alone for stage 2 frozen shoulder, though the long-term difference was marginal [20].

The combination approach of hydrodilatation with physiotherapy and steroid provides optimal outcomes. Cho et al. (2024) in a randomized controlled trial demonstrated that combination therapy

(hydrodilatation plus subdeltoid bursa injection with corticosteroid and mobilization) was superior to physiotherapy alone, with effects persisting for at least 6 months [21]. Challoumas et al. (2020) in a JAMA Network Open systematic review and meta-analysis confirmed that combined approaches yielded the most consistent improvements across pain, function, and ROM outcomes [22].

In our study, at one month, 64.3% achieved excellent CSS scores, 19% good, 11.9% mediocre, and 4.8% poor outcomes. These results are comparable with Sundharajan et al. who found significant improvement in pain, ROM, and functional ratings ($P < 0.001$) with both MUA and arthroscopic capsular release, without significant difference between the two groups at 24 weeks. Our study aligns with Zhang et al. (2021), who in a network meta-analysis confirmed hydrodilatation with corticosteroid as one of the most effective non-surgical treatment strategies for frozen shoulder [23].

There is a significant improvement in the entire range of shoulder movements in our study, but further long-term follow-up is needed to assess any recurrence of symptoms. Castelhana et al. (2023) emphasised that optimizing physiotherapy after MUA reduces recovery time and recurrence rates [24]. Takahashi et al. (2024) identified diabetes mellitus as a significant risk factor for recurrence after shoulder manipulation, highlighting the need for closer monitoring in this subgroup [25].

Conclusion

Frozen shoulder was more commonly observed among females in the 40–49-year age group, with a higher

involvement of the non-dominant shoulder and a notable association with diabetes mellitus. The present study demonstrates that manipulation with hydrodilatation combined with intra-articular corticosteroid is associated with significant short-term improvement in pain, range of motion, and functional status as assessed by the Constant Shoulder Score. These findings suggest that the intervention may be an effective option for early symptomatic relief in patients not responding to conservative management.

The findings of this study have important clinical implications, particularly in resource-limited settings, where access to advanced surgical interventions may be constrained. Manipulation with hydrodilatation combined with intra-articular corticosteroid represents a relatively simple, cost-effective, and minimally invasive treatment option that can be performed in a tertiary care setting, offering early symptomatic relief and improved functional outcomes in patients with frozen shoulder who do not respond to initial conservative management

Limitations

This study has certain limitations that should be considered while interpreting the findings. A formal sample size calculation was not performed, and a universal sampling method was adopted, wherein all eligible patients presenting during the study period were included, resulting in a relatively small sample size. The absence of a control or comparison group limits the ability to draw definitive conclusions regarding the comparative effectiveness of the intervention. The follow-up duration was limited to one month, as the study was designed to assess short-term outcomes, and therefore long-

term functional improvement, recurrence, and sustainability of treatment effects could not be evaluated. Being a single-center study, the generalizability of the findings may also be limited. Further studies with larger sample sizes, appropriate control groups, and longer follow-up are warranted to validate these findings.

Statements and Declarations

Conflicts of interest

The authors declare that they do not have conflict of interest.

Funding

No funding was received for conducting this study.

Data availability statement

The datasets generated and analysed in this study are available from the corresponding author on reasonable request. They are not publicly shared because they contain sensitive information that could indirectly identify participants.

Ethical Approval

Ethical approval was obtained from the Institutional Ethics Committee of Dhanalakshmi Srinivasan Medical College and Hospital (Certificate No. IECHS/IRCHS/DSMCH/293, dt:07.03.2023).

Informed Consent

Informed consent was obtained from all participants after explaining the study procedures, risks, and benefits, including consent for participation and publication of anonymised data with assurance of confidentiality and privacy.

References

1. Singh S, Gill S, Mohammad F, Kumar S, Kumar D, Kumar S. Prevalence of shoulder disorders in tertiary care centre. *Int J Res Med Sci.* 2015;3(4):917.
2. Millar NL, Meakins A, Struyf F, Willmore E, Campbell AL, Kirwan PD, et al. Frozen shoulder. *Nat Rev Dis Primers.* 2022;8(1):59. doi:10.1038/s41572-022-00386-2
3. St Angelo JM, Fabiano SE. Adhesive Capsulitis. In: *StatPearls [Internet]. Treasure Island (FL): StatPearls Publishing; 2023.*
4. Kraal T, Lubbers J, van den Bekerom MPJ, Alessie J, van Kooyk Y, Eygendaal D. The puzzling pathophysiology of frozen shoulders: a scoping review. *J Exp Orthop.* 2020;7(1):91. doi:10.1186/s40634-020-00307-w
5. Dyer BP, Rathod-Mistry T, Burton C, van der Windt D, Bucknall M. Diabetes as a risk factor for the onset of frozen shoulder: a systematic review and meta-analysis. *BMJ Open.* 2023;13(1):e062377. doi:10.1136/bmjopen-2022-062377
6. Kim JH, Kim BS, Han K, Kwon HS. The risk of shoulder adhesive capsulitis in individuals with prediabetes and type 2 diabetes mellitus: a longitudinal nationwide population-based study. *Diabetes Metab J.* 2023;47(6):869-878. doi:10.4093/dmj.2022.0275
7. Pandey V, Madi S. Clinical guidelines in the management of frozen shoulder: an update! *Indian J Orthop.* 2021;55(2):299-309. doi:10.1007/s43465-020-00313-x
8. Lädermann A, Piotton S, Abrassart S, Mazzolari A, Ibrahim M, Stirling P. Hydrodilatation with corticosteroids is the most effective conservative management for frozen shoulder. *Knee Surg Sports Traumatol Arthrosc.* 2021;29(8):2553-2563. doi:10.1007/s00167-020-06390-x
9. Poku D, Hassan R, Migliorini F, Maffulli N. Efficacy of hydrodilatation in frozen shoulder: a systematic review and meta-analysis. *Br Med Bull.* 2023;147(1):121-147. doi:10.1093/bmb/ldad018
10. Latzka J, Shoup L, Baird MH, et al. Hydrodilatation versus corticosteroid injection in treatment for adhesive capsulitis. *PM&R.* 2023;15(12):1580-1587. doi:10.1002/pmrj.13094
11. Leafblad N, Mizels J, Tashjian R, Chalmers P. Adhesive capsulitis. *Phys Med Rehabil Clin N Am.* 2023;34(2):453-468. doi:10.1016/j.pmr.2022.12.009
12. Challoumas D, Biddle M, McLean M, Millar NL. Comparison of treatments for frozen shoulder: a systematic review and meta-analysis. *JAMA Netw Open.* 2020;3(12):e2029581. doi:10.1001/jamanetworkopen.2020.29581
13. Dyer BP, Burton C, Rathod-Mistry T, Blagojevic-Bucknall M, van der Windt DA. Diabetes as a prognostic factor in frozen shoulder: a systematic review. *Arch Rehabil Res Clin Transl.* 2021;3(3):100141. doi:10.1016/j.arrct.2021.100141
14. Krishna Avulapatti S. Periarthritis shoulder: Effect of manipulation under general anesthesia on pain and range of movement. *IJOS.* 2020;4(4):342-347.
15. Yao H, Wu G, Zhong Y. Efficacy of hydrodistension for frozen shoulder: a systematic review and meta-analysis. *Medicine (Baltimore).*

- 2024;103(22):e38388. doi:10.1097/MD.00000000000038388
16. Wang JC, Hsu PC, Wang KA, et al. Comparative effectiveness of corticosteroid dosages for ultrasound-guided glenohumeral joint hydrodilatation in adhesive capsulitis: a randomized controlled trial. *Arch Phys Med Rehabil.* 2023;104(5):745-752. doi:10.1016/j.apmr.2022.11.009
 17. Song C, Yu W, Jiang W, et al. Outcome of manipulation under anesthesia with or without intra-articular steroid injection for treating frozen shoulder: a retrospective cohort study. *Medicine (Baltimore).* 2021;100(13):e23893. doi:10.1097/MD.00000000000023893
 18. Xu Q, Li H, Jiang D, et al. The effect of manipulation under anesthesia for secondary frozen shoulder: a randomized controlled trial. *Pain Ther.* 2022;11(4):1373-1387. doi:10.1007/s40122-022-00438-1
 19. Salomon M, Pastore C, Maselli F, Di Bari M, Pellegrino R, Brindisino F. Manipulation under anesthesia versus non-surgical treatment for patients with frozen shoulder contracture syndrome: a systematic review. *Int J Environ Res Public Health.* 2022;19(15):9715. doi:10.3390/ijerph19159715
 20. Kraal T, de Wit Y, The B, van Boekel L, Koenraadt-van Oost I, Boer R, et al. Improved range of motion after manipulation under anesthesia versus physiotherapy for stage two frozen shoulder: a randomized controlled trial. *JSES Int.* 2024;8(2):293-298. doi:10.1016/j.jseint.2023.11.004
 21. Cho CH, Kim DH, Lee YK, Bae KC. Efficacy of combination therapy (hydrodilatation and subdeltoid bursa injection with corticosteroid, mobilization, and physical therapy) vs physical therapy alone for treating frozen shoulder: a randomized single-blind controlled trial. *Arch Phys Med Rehabil.* 2024;105(4):725-732. doi:10.1016/j.apmr.2023.11.010
 22. Zhang J, Zhong S, Tan T, et al. Comparative efficacy and patient-specific moderating factors of nonsurgical treatment strategies for frozen shoulder: an updated systematic review and network meta-analysis. *Am J Sports Med.* 2021;49(6):1669-1679. doi:10.1177/0363546520956293
 23. Pimenta M, Vassalou EE, Dimitri-Pinheiro S, Klontzas ME, Ramos I, Karantanas AH. Ultrasound-guided hydrodistension for adhesive capsulitis: is there any adjunct effect of immediate post-procedural manipulation over instructed physical therapy? *J Ultrasound Med.* 2022;42(3):665-674. doi:10.1002/jum.16063
 24. Castelhana R, Woods J, Akehurst H, Mitra A, James M, Berntzen B, et al. Optimising the use of physiotherapy resources after manipulation under anaesthetic for frozen shoulder. *Ann R Coll Surg Engl.* 2023;105(2):136-141. doi:10.1308/resann.2022.0016
 25. Takahashi R, Kajita Y, Harada Y, Iwahori Y, Miyashita N, Deie M. Risk factors for recurrence of frozen shoulder after shoulder manipulation under ultrasound-guided cervical nerve root block. *JSES Int.* 2024;8(1):90-94. doi:10.1016/j.jseint.2023.09.002